

Multi-centric European post-market follow-up study of the Neuroform Atlas Stent System: primary results

Pierre-Henri Lefevre ¹, Peter Schramm,² André Kemmling,³ Xavier Barreau,⁴ Gaultier Marnat ⁴, Michel Piotin,⁵ Ansgar Berlis,⁶ Isabel Wanke,⁷ Alain Bonafe ¹, Emmanuel Houdart,⁸ ATLAS EU PMCF Investigators

► Additional supplemental material is published online only. To view, please visit the journal online (<http://dx.doi.org/10.1136/neurintsurg-2021-017849>).

For numbered affiliations see end of article.

Correspondence to

Dr Pierre-Henri Lefevre, Neuroradiology department, Hôpital Gui de Chauliac Service de Neuroradiologie, 34295 Montpellier, France; [ph.lefevre30@gmail.com](mailto:lefevre30@gmail.com)

Received 7 June 2021
Accepted 3 August 2021

ABSTRACT

Background Few prospective series have described the safety and effectiveness of the Neuroform Atlas Stent System. We aimed to investigate the efficacy and safety of the device in patients treated for unruptured aneurysm.

Methods ATLAS EU PMCF is a consecutive, prospective, multicentric study that included patients with unruptured saccular aneurysm of all sizes. Follow-up visits were scheduled at 3–6 months and 12–16 months with digital subtraction angiography (DSA) or MRI imaging follow-up as per the site standard of care. The primary efficacy endpoint was adequate aneurysm occlusion (Raymond Roy occlusion grade I and II) on 12 month angiography. The primary safety endpoint was any major stroke or ipsilateral stroke or neurological death within 12 months.

Results Of the 106 patients consented, 105 were treated with at least one Neuroform Atlas stent. There was a failed implantation attempt in 1 patient, 85 patients received lateral stenting, and 19 patients received Y-stenting. Mean aneurysm neck size was 4.2 mm (range 1.9–33 mm). Adequate occlusion was observed in 95.1% immediately after the procedure and in 98.9% of cases at 1 year DSA follow-up. Overall, 1.0% (1/102; 95% CI 0.0% to 5.3%) of patients experienced a primary safety endpoint of major stroke. Three minor strokes resulted in a modified Rankin Scale score of 2.

Conclusions In this multicentric, prospective study, stent-assisted coiling of medium size unruptured aneurysms with the Neuroform Atlas stent resulted in a favorable rate of satisfactory occlusion. In our findings, the use of the Y-stenting technique was associated with increased rates of procedural complications.

Clinical trial registration <https://clinicaltrials.gov/ct2/show/NCT02783339>.

is suitable for a 0.017 inch microcatheter delivery. Initial experiences consisting of mostly retrospective and single centered investigations were published, but limitations were noted due to their study designs and a lack of patients or follow-up.^{3–13} We therefore conducted a prospective and multicentric post-market study to determine the clinical and technical outcomes following treatment of intracranial aneurysms with the Neuroform Atlas stent.

METHODS

Study design

The European Atlas post-market clinical follow-up study (ATLAS EU PMCF) was a prospective, observational, single arm, multicentric cohort which included patients with unruptured or previously ruptured (≥ 3 months) intracranial aneurysms. Each investigating center obtained institutional review board or ethics committee approval. Patients were enrolled between October 2016 and February 2018 at 11 hospital centers.

The primary safety endpoint was the permanent morbidity and mortality rate at 1 year post-procedure, defined as any neurological death or major ipsilateral stroke leading to an increase of ≥ 4 points in the National Institutes of Health Stroke Scale (NIHSS) at 24 hours and associated worsening of the modified Rankin Scale (mRS) ≥ 3 or change from baseline by 2 points at 90 days post-event. A stroke with clinical symptoms that resolved within 24 hours and with brain imaging showing infarction of vascular origin was considered a minor stroke.

Secondary endpoints were designed to provide information about effectiveness and angiographic results of the Neuroform Atlas Stent System and were as follows:

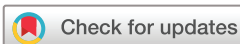- Procedural technical success (accurate stent delivery, accurate positioning)
- Aneurysm occlusion status (Raymond Roy score) assessed at 1 year (12 to 16 months) post-procedure follow-up by digital subtraction angiography (DSA)
- In-stent stenosis ($> 50\%$ of the arterial diameter)
- Incidence of retreatment occurring 12 to 16 months post-procedure.

Secondary safety endpoints were studied, such as the rates of all intraprocedural adverse events and device malfunctions, symptomatic and asymptomatic adverse events that occurred during follow-up, subarachnoid hemorrhage (SAH), aneurysm rupture/re-rupture rate, new or worsening

INTRODUCTION

Wide-neck or aneurysms with unfavorable morphology have always been a challenge for endovascular treatment. Many improvements in the endovascular field such as the remodeling technique or intracranial stenting have led to endovascular treatment options for most types of aneurysms.^{1 2}

Among these advances, the Neuroform Atlas stent was designed as an open-cell stent to address the challenges with tortuous anatomy. Treatment has been frequently impeded due to improper microcatheter size and limited access to the target aneurysm. Designed to address this, the Neuroform Atlas stent



© Author(s) (or their employer(s)) 2021. No commercial re-use. See rights and permissions. Published by BMJ.

To cite: Lefevre P-H, Schramm P, Kemmling A, et al. *J NeuroIntervent Surg* Epub ahead of print: [please include Day Month Year]. doi:10.1136/neurintsurg-2021-017849

major ipsilateral stroke measured by NIHSS and mRS, and the duration between the index procedure and the occurrence of major ipsilateral stroke or death.

Inclusion and exclusion criteria

Patients aged 18 years or older harboring an unruptured or previously ruptured (≥ 3 months) intracranial aneurysm in the anterior and posterior circulation treated with the Neuroform Atlas stent were eligible to enroll in this study. All patients provided a signed informed consent in order to participate. Key exclusion factors included patients with an mRS ≥ 3 , previously ruptured target aneurysm ≤ 3 months before, fusiform aneurysms, multiple aneurysms (except adjacent aneurysms being treated by the same stent), aneurysms associated with an arteriovenous malformation or potential hemorrhagic complications, and aneurysms previously treated with stenting other than the Neuroform Atlas Stent System. Pregnant or child-feeding patients and those with contraindications to MR imaging, nitinol (due to allergy), heparin, clopidogrel or aspirin were also excluded.

Endovascular procedures

Each procedure was performed via a femoral approach with the patient under general anesthesia. Most of the patients received an initial heparin bolus (70–100 UI/kg) followed by continuous infusion (targeted activated clotting time between 250–300 s). Antiplatelet drugs were administered under the direction and management of each participating investigator according to each institution's standard of care protocol. The aneurysm and the parent vessel were analyzed via angiography before stent placement.

Patients were treated with the Neuroform Atlas Stent System using various coiling techniques. The jailing technique that secured the microcatheter between the stent and the vessel wall was used in 60.9% (64/105) of cases, insertion of the microcatheter through the stent struts (eg, recrossing) was used in 32.4% (34/105) of cases, and post-coiling was used in the remaining 6.7% (7/105) of cases.

Clinical evaluations

Clinical evaluations were performed before and after the index procedure, before hospital discharge, at 3–6 months post-procedure, and 12–16 months post-procedure. Neurological status and mRS were compared with initial baseline measures for indicators of clinical improvement or worsening. All the clinical events were classified according to a written prespecified protocol and adjudicated by an independent clinical events committee (CEC).

Radiological evaluation

An independent core laboratory reviewed all the images via a central database. The modified Raymond Roy scale was used to classify the occlusion as complete, residual neck, or residual aneurysm based on the working projections.¹⁰ Radiological follow-up was collected at 3–6 months and 12–16 months post-procedure per institutional standards. The occlusion status was compared with post-procedural results to determine the rates of progressive occlusion defined as any perceptible improvement from the initial results. Recurrence was classified as minor or major and the latter was defined as a requirement of subsequent treatment.

Clinical characteristics

Of the 106 consented patients, 105 patients with successful implantation of one or more Neuroform Atlas stents were

reported, as shown in online supplemental figure 1. Patients who were consented, enrolled, and successfully received a stent device implant were counted as the modified intention to treat (mITT) group. Of the mITT group patients, 79 (75.2%) were female with a mean age of 55.3 years (range 28–81 years). Twenty-five (23.8%) patients reported having a previous non-target aneurysm, of which 11 (10.5%) reported previous rupture.

Pre-procedure medication usage

No antiplatelet protocol was prespecified in this study. Treatments were given according to the local institutional standard of care protocol and at the discretion of the physician investigator. Most of the patients (61.9%; 65/105) benefited from dual antiplatelet therapy (DAPT) administered pre-procedure, consisting of aspirin and one or more P2Y₁₂ inhibitors. Among them, 46 (43.8%) received clopidogrel, 19 (18.1%) received ticagrelor, three (2.9%) received prasugrel, two (1.9%) received clopidogrel + prasugrel, and one (1.0%) received clopidogrel + ticagrelor.

RESULTS

Characteristics of target aneurysms

The majority of aneurysms treated were between 4–7 mm in diameter (55.2%; 58/105). Most treated aneurysms had a wide neck with a dome-to-neck ratio lower than 1.5 (57.1%; 60/105). The shape of the treated aneurysm was spherical in most cases (46.7%; 49/105). The mean aneurysm size was 4.9 mm (range 1.8–17 mm) and the mean neck width was 4.2 mm (range 1.9–33 mm). The target aneurysm had been previously treated in 19 (18%) patients. Anterior circulation target aneurysm locations represented 90.5% (95/105) of cases. The most common location was the middle cerebral artery (MCA), seen in 40 patients (38%). Details regarding target aneurysm characteristics are included in [table 1](#).

Technical results

The overall reported procedure technical success was 94.7% (124/131). The reported accurate stent positioning was 94.7% (124/131) and accurate delivery was 96.9% (127/131). The median procedure duration was 95 min (range 35–375 min). All patients received general anesthesia (100%; 105/105).

In descending order and when analyzed per patient, the number of stents most commonly used was one device (78.1%; 82/105), two devices (20.0%; 21/105), three devices (1.0%; 1/105), and four devices (1.0%; 1/105). Similarly, for number of stents successfully implanted on a per patient level, patients received one device (81.0%; 85/105), two devices (17.1%; 18/105), or three devices (1.9%; 2/105). In procedures utilizing more than one stent, 90.5% (19/21) utilized Y-stenting and in two other cases additional stenting techniques were needed. The median coil packing density was 30.1% and the mean was $47.1 \pm 31.1\%$. Detailed technical results are available online (see online supplemental material).

Permanent morbidity and mortality

Primary safety endpoint findings in relation to morbidity and mortality as adjudicated by the CEC, including ipsilateral strokes, are included in [table 2](#).

There was an overall device complication rate of 5.7% (6/105) through 1 year follow-up: there was one peri-procedural vascular stent thrombosis and five events were recorded (four in the post-procedural days 1–180, one of late occurrence after day 181).

Table 1 Target aneurysm characteristics (mITT)

Aneurysm characteristics	Results
Aneurysm neck width (mm)	
Mean±SD (N)	4.2±3.1 (105)
Median (Q1–Q3)	3.8 (3–4.5)
Range (min–max)	31.1 (1.9–33)
Aneurysm size (mm)*	
Mean±SD (N)	5.8±2.5 (105)
Median (Q1–Q3)	5.3 (4–6.7)
Range (min–max)	14.5 (2.5–17)
Aneurysm size by categories (mm)*	
<4 mm	21.0% (22/105)
≥4 mm and <7 mm	55.2% (58/105)
≥7 mm and <10 mm	19.0% (20/105)
≥10 mm	4.8% (5/105)
Dome/neck ratio	
<1.5	57.1% (60/105)
Aneurysm discovery	
Incidental	77.4% (82/105)
Symptomatic	4.7% (5/105)
Previously ruptured	12.4% (13/105)
Recanalization	5.7% (6/105)
Anterior location	
Anterior cerebral artery (ACA)	13.3% (14/105)
Anterior communication artery (ACom)	14.3% (15/105)
Internal carotid artery (ICA)	24.8% (26/105)
Middle cerebral artery (MCA)	38.1% (40/105)
Posterior location	
Basilar artery (BA)	4.8% (5/105)
Posterior cerebral artery (PCA)	2.9% (3/105)
Posterior inferior cerebral artery (PICA)	1.0% (1/105)
Vertebrobasilar (VB)	1.0% (1/105)

*Aneurysm size calculated from the maximum of dome height, dome width and dome depth.
mITT, modified intention to treat.

Site-reported technical results and perioperative information is provided in online supplemental table 1.

Major and minor strokes

Overall, there were five (4.8%) and eight (7.6%) patients who experienced major and minor ipsilateral strokes, respectively. When adjusting for major ipsilateral strokes per NIHSS criteria only, there were five major ipsilateral strokes reported with three of them being device-related and occurring during the peri-procedural treatment time. Among the device-related major strokes, there were two deemed to be of thrombotic causes and one was due to vessel perforation. Of the five major ipsilateral strokes, there were two which occurred later at day 46 and day 60 post-procedure.

There was one major stroke reported as medication-related, which was due to an improper withdrawal from clopidogrel by the patient.

One case was noted as vessel perforation with subsequent parenchymal hemorrhage, potentially due to difficulty navigating the microcatheter. Post-procedure angiogram showed contrast leak in the left parietal area which was confirmed by CT demonstrating a temporal SAH before the patient expired. The case was recorded as a device misplacement during the procedure and

was deemed to be unrelated to the device delivery system, but related to the index procedure. This case met the primary safety endpoint criteria per ATLAS EU PMCF definition.

Minor strokes

There were eight minor ipsilateral strokes reported and four were device related. Of the device-related minor strokes, three were also deemed to be related to the index procedure. Two minor strokes were attributed solely to the index procedure. One minor stroke was related to medication with unknown relationship to the device. The final minor stroke was related to a pre-existing condition.

Deaths

Two patients died during the study, one from a pulmonary carcinoma and one following procedure difficulties to navigate the microcatheter, which led to vessel perforation resulting in SAH and neurological death. Both deaths were deemed unrelated to the stent device and delivery system according to CEC adjudication. The latter patient death was deemed to be related to the index procedure.

Other complications

Apart from intracranial complications, two (1.9%) patients had a puncture site hematoma and two (1.9%) patients experienced a contrast encephalopathy. No patients in the study were observed to have target aneurysm ruptures through 1 year post-procedure in the mITT population, as confirmed by the CEC.

Post-procedure medication

A majority of patients (88.6%; 93/105) benefited from DAPT therapy at the time of discharge, consisting of aspirin and one or more P2Y₁₂ inhibitors. Among them, 61 (58.1%) received clopidogrel, 27 (25.7%) received ticagrelor, eight (7.6%) received prasugrel, and three received clopidogrel + prasugrel.

Occlusion status

Per core lab assessment, complete occlusion as defined by the Raymond Roy Occlusion Classification class I, was seen in 91.3% in the perioperative period. Complete occlusion was seen in 97.4% and 90.3% of patients at 3–6 month and 12–16 month follow-up visits, respectively. Angiographic findings regarding occlusion status are summarized in table 3.

Table 2 CEC-adjudicated permanent morbidity and mortality (major ipsilateral stroke or neurological death through 1 year) (mITT)

Analysis	% Subject (n/N) (# event)	95% CI*	P value
Permanent morbidity and mortality (major ipsilateral stroke or neurological death)	1.0% (1/102)	0.0% to 5.3%	<0.001
Neurologic death	1.0% (1/102)	0.0% to 5.3%	
Major ipsilateral stroke	1.0% (1/102)	0.0% to 5.3%	
Major ipsilateral stroke per NIHSS†	4.9% (5/102)	1.6% to 11.1%	
Major ipsilateral stroke per mRS‡	1.0% (1/102)	0.0% to 5.3%	
Worst case scenario§	3.8% (4/105)	1.0% to 9.5%	<0.001
Best case scenario	1.0% (1/105)	(0.0%, 5.2%)	<0.001

*Clopper-Pearson exact confidence interval.

†NIHSS decline ≥4 points lasting 24 hours or more.

‡mRS ≥3 at a minimum of 90 days post-event.

§Missing endpoint data were imputed as failure.

CEC, clinical events committee; mITT, modified intention to treat; mRS, modified Rankin Scale; NIHSS, National Institutes of Health Stroke Scale.

Table 3 Occlusion status according to Raymond Roy classification reviewed by core lab (mITT)

	Post-procedure*	3–6 months*	1 Year*
Complete occlusion Raymond Roy I	91.3% (94/103)	97.4% (37/38)	90.3% (84/93)
Aneurysm neck Raymond Roy II	3.9% (4/103)	0.0% (0/38)	8.6% (8/93)
Incomplete occlusion Raymond Roy III	4.9% (5/103)	2.6% (1/38)	1.1% (1/93)
Adequate occlusion Raymond Roy I or II	95.1% (98/103)	97.4% (37/38)	98.9% (92/93)

*As observed.
mITT, modified intention to treat.

Parent artery stenosis

Among the 93 patients who had an imaging follow-up at 1 year, 63 (67.7%) had no or lower than 25% parent artery stenosis, six (6.5%) were between 25% and 50%, and none were greater than 50%. The remaining 24 (25.8%) patients were not assessed due to inaccessible records. One year follow-up imaging was undertaken per institutional standard of care. When MR angiography or CT angiography were the chosen modalities, the aneurysmal occlusion was core lab assessable but the stenosis status was not.

Modified Rankin Scale

At 12–16 month follow-up, 73 (76.0%) patients had an mRS of 0, 18 (18.8%) had an mRS of 1, and three (3.1%) had an mRS of 2. There were two (2.1%) patient deaths, one related to the intervention and one related to another medical condition (cancer), which were deemed to be unrelated to the device implant or delivery system and which were counted as an mRS of 6. Observed changes in reported mRS evaluations are displayed in [table 4](#).

DISCUSSION

This multicentric prospective study included elective aneurysmal treatment with the Neuroform Atlas stent and is the largest of its kind to date in Europe. This study demonstrated a high technical success rate with an accurate delivery reported as high as 96.9%. This rate is similar to current low-profile stents such as the LVIS Jr and Leo Baby.^{13–15}

Adequate occlusion, as defined by grade I and II according to the Raymond Roy classification, was seen in 98.9% of the 93 patients that completed the follow-up with DSA. This result is

Table 4 mRS scores at baseline, 3–6 month follow-up, and 12–16 month follow-up (mITT)

mRS score	Baseline	3–6 month follow-up % (n/N)*	12–16 month follow-up % (n/N)†
0	81.0% (85/105)	76.2% (77/101)	76.0% (73/96)
1	17.1% (18/105)	18.8% (19/101)	18.8% (18/96)
2	1.9% (2/105)	4.0% (4/101)	3.1% (3/96)
6		1.0% (1/101)	2.1% (2/96)

*One patient died before discharge after per procedural perforation.

†One patient died of unrelated disease before 12 month follow-up visit. mRS score was imputed.

mITT, modified intention to treat; mRS, modified Rankin Scale.

slightly higher than other studies and likely attributable to the longer post-procedure follow-up protocol as compared with other investigations.^{8 12 13 16} The additional composite primary efficacy endpoint of complete aneurysm occlusion (Raymond Roy I) without significant (>50%) parent artery stenosis or aneurysm retreatment was achieved in 89.9% (95% CI 80.2% to 95.8%) of patients.

The completion rate of follow-up assessments was high with only three patients lost to follow-up (LTFU) and 93 patients (88.5%) completing vascular imaging at 12 months. The latter is significantly higher than that reported in previous published investigations.^{5 8 12 13 16}

The rate of permanent morbidity and mortality was 1.0% (1/105; $p < 0.001$, 95% CI 0.0% to 5.2%) in the best-case analysis. Regarding morbidity and mortality findings and device-related events, there was one major ipsilateral stroke per safety endpoint criteria and three minor strokes resulting in an mRS score of 2. Alternatively, the rate of permanent morbidity and mortality was estimated at 3.8% (4/105, $p < 0.001$, 95% CI 1.0%, 9.5%) in the worst-case analysis, accounting for three LTFU patients. This rate seems higher than previously published series including only unruptured aneurysms.^{4 7 9 13 17 18} This relatively higher rate is likely attributable to the more comprehensive follow-up (every event was tracked and counted), the lack of a prespecified antiplatelet protocol, and the relatively high proportion of Y-stenting procedures.

There were 19 patients included in the present analysis who were treated with Y-stenting. Our experience in the ATLAS EU PMCF study supports the notion that open cell stenting, such as with the Neuroform Atlas Stent System, is particularly suitable for this kind of technical approach, allowing treatment of wide neck aneurysms through a 0.017 inch catheter. Nevertheless, it has been extensively reported that this technique suffers from a higher rate of morbidity.¹⁹ Ciccio *et al* reported recently up to 12.7% of symptomatic complications in 55 patients treated with Y-stenting which was associated with a permanent neurological morbidity rate of 3.6%.¹⁷ Similar results were shared by Aydin *et al* who reported a 3.3% permanent neurological morbidity rate among 30 patients treated with Y-stenting.³ Contrary to other published investigations^{7 12 13} which included smaller quantities of Y-stenting procedures, our study involving the use of open cell stents reported a low morbidity rate of 1% within the 18% of study patients treated with Y-stenting. However, the only patient who died secondary to intracranial perforation was also treated with Y-stenting.

No patient experienced a parent artery stenosis >50% and only one stent thrombosis was reported. This result is significantly lower than other published reports with braided stents.²⁰ It has been postulated that a braided design is slightly more thrombogenic and the present work may support this hypothesis.²¹

Compared to the American literature,^{7 12 22} we observed a higher proportion of MCA aneurysms (38.1%) and lower mean diameter in the ATLAS EU PMCF study. There was 21% of patients who had an aneurysm diameter lower than 4 mm. Hence, this could partially explain the higher reported rate of occlusion during follow-up as previously shown by Caragliano *et al* in a similar Italian registry study.²³ Comparison with a similar prospective trial shows that our morbidity rate is comparable with 4.8% of patients experiencing major stroke as compared with 4.4% in the Atlas IDE trial.²³ In the Atlas IDE trial, two stents were used in 15.9% of patients, which is comparable to the proportion of Y-stenting in our cohort. Interestingly, even though aneurysms lower than 4 mm were excluded from the Atlas IDE trial, efficacy rates regarding occlusion were very

similar to ours with 96.1% of Raymond Roy I and II as compared with 98.9% in the present study. Recently, a sub-analysis from the ATLAS IDE data about the MCA aneurysm treatment was published.²⁴ Since ATLAS EU contains more MCA aneurysms, sub-analysis from this dataset will be undertaken in the future.

Stent-assisted coiling (SAC) for small and medium size (4 to 9 mm) wide neck unruptured aneurysms is a competitive technology compared with intrasaccular devices and flow diverters. The SAC and the intrasaccular devices are prone to recanalization but retreatment appears easier after SAC procedures.²⁵ Flow diverters may carry the risk of side branch occlusion in the long term.²⁶

We acknowledge that this study suffers several limitations such as the non-randomized design, which could include a selection bias and the lack of a control group with a different stent device. Likewise, no antiplatelet protocol was agreed before inclusion, therefore each center protocol was localized. This resulted in different results among centers in terms of drug usage and dosage, but also reflects 'real life' usage of such products.

CONCLUSION

The ATLAS EU PMCF study is the first multicentric and prospective study regarding the Neuroform Atlas Stent System in Europe. The results show that the Neuroform Atlas stent is a relatively safe and very efficient method to treat unruptured saccular aneurysms of all sizes.

Author affiliations

¹Neuroradiology department, Gui de Chauliac Hospital Montpellier University Hospital, Montpellier, France

²Department of Neuroradiology, University Medical Center Schleswig-Holstein, Luebeck, Germany

³Institute of Neuroradiology, University Medical Center Schleswig-Holstein, Luebeck, Germany

⁴Interventional and Diagnostic Neuroradiology, Bordeaux University Hospital, Bordeaux, France

⁵Department of Interventional Neuroradiology, Fondation Rothschild Hospital, Paris, France

⁶Department of Diagnostic and Interventional Neuroradiology, Klinikum Augsburg, Augsburg, Bayern, Germany

⁷Neuroradiology Department, Hirslanden Clinic, Zurich, Switzerland

⁸Neuroradiology Department, Lariboisière Hospital, Paris, France

Collaborators ATLAS EU PMCF Investigators and coordinators: Ansgar Berlis, Christoph Maurer, Martin Seidler, Ilse Kummer, Sabine Hanisch, Gabriele Jochum-Pfeilsticker, Marius Hartmann, Steffen Reissberg, Sascha Schiffler, Nadja Rieckehr, Werner Weber, Annika Kowoll, Anushe Weber, Sebastian Fischer, Mara Postert, Peter Schramm, Thomas Eckey, André Kemmling, Alexander Neumann, Ramona Schramm, Alain Bonafé, Vincent Costalat, Carlos Riquelme, Pierre-Henri Lefevre, Grégory Gasco, Marinette Moynier, Emmanuel Houdart, Vittorio Civelli, Alexis Guédon, Jean-Pierre Saint-Maurice, Marc-Antoine Labeyrie, Alexandre Parpaleix, Baptiste Bonnet, Kamil Zelenak, Jana Zelenakova, Branislav Kolarovszki, Michel Piotin, Raphael Blanc, Stanislas Smajda, Jean-Philippe Desilles, Gabriele Ciccio, Robert Fahed, Hocine Redjem, Mylène Hamdani, Malek Ben Maacha, Lucia Lopes, Xavier Barreau, Gaultier Marnat, Florent Maire, Marine Premont, Laura Albizu, Jean-Christophe Gentric, Julien Ognard, Géraldine Viard, Ana Paula Narata, Vladimir Charron, Nicolas Charron

Contributors The last two authors contributed equally to the manuscript. All authors made substantial contributions to the conception and design, analysis, and interpretation of data; drafted or critically revised the article; and gave final approval of the version to be published.

Funding The ATLAS EU PMCF study (Evaluation of Safety and Performance of the Neuroform Atlas™ Stent System for Intracranial Aneurysm Treatment – Post Market Clinical Follow-up) was funded by Stryker Neurovascular (Fremont, California, United States).

Competing interests P-HL reports paid lectures with Stryker, Medtronic and Phenox outside the present study. PS reports speaker honoraria and travel support from Penumbra, Phenox and Stryker outside the present study. AK reports consulting and proctoring activities with Phenox, Penumbra, Stryker, Acandis outside the present study. XB reports service and related fees with Stryker outside this study and within

past 3 years. Proctored or received service-related fees from MicroVention (Proctor). GM reports paid lectures with Microvention and Medtronic. MP reports shares in Basecamp Vascular. ABE reports a proctoring activity for Stryker outside this study and within past 3 years, proctored or received service-related fees from MicroVention (Proctor), Sequent Medical (Proctor), Phenox (lecture honorary, CEC), and Penumbra (lecture honorary). IW is speaker for Bayer, not related to the product. ABo is consultant for Stryker, Balt and Phenox. EH is the principal investigator of the present ATLAS EU study.

Patient consent for publication Not required.

Ethics approval The study was performed in accordance with International Standard ISO 14155, Declaration of Helsinki, Good Clinical Practice (GCP), International Conference on Harmonization (ICH), and/or any other applicable guidelines and applicable local regulations, whichever affords greater protection to the patient. Adverse event data were collected and analyzed per MDD 93/42/EEC and MEDDEV 2.12.1 guidelines.

Provenance and peer review Not commissioned; externally peer reviewed.

Data availability statement Data may be obtained from a third party and are not publicly available.

Supplemental material This content has been supplied by the author(s). It has not been vetted by BMJ Publishing Group Limited (BMJ) and may not have been peer-reviewed. Any opinions or recommendations discussed are solely those of the author(s) and are not endorsed by BMJ. BMJ disclaims all liability and responsibility arising from any reliance placed on the content. Where the content includes any translated material, BMJ does not warrant the accuracy and reliability of the translations (including but not limited to local regulations, clinical guidelines, terminology, drug names and drug dosages), and is not responsible for any error and/or omissions arising from translation and adaptation or otherwise.

ORCID iDs

Pierre-Henri Lefevre <http://orcid.org/0000-0002-6196-3869>

Gaultier Marnat <http://orcid.org/0000-0002-7611-7753>

Alain Bonafé <http://orcid.org/0000-0002-9187-1375>

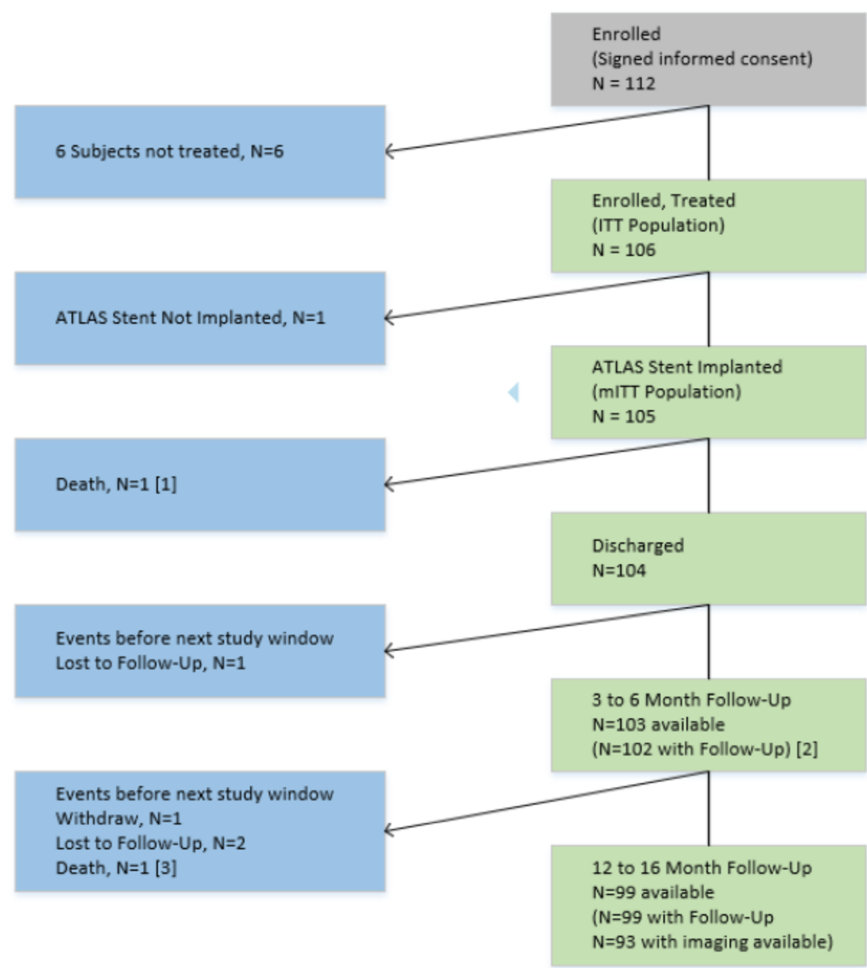
REFERENCES

- King B, Vaziri S, Singla A, *et al.* Clinical and angiographic outcomes after stent-assisted coiling of cerebral aneurysms with enterprise and Neuroform stents: a comparative analysis of the literature. *J Neurointerv Surg* 2015;7:905–9.
- Moret J, Cognard C, Weill A, Castaings L, *et al.* [Reconstruction technic in the treatment of wide-neck intracranial aneurysms. Long-term angiographic and clinical results. Apropos of 56 cases]. *J Neuroradiol* 1997;24:30–44.
- Aydin K, Balci S, Sencer S, *et al.* Y-stent-assisted coiling with low-profile Neuroform Atlas stents for endovascular treatment of wide-necked complex intracranial bifurcation aneurysms. *Neurosurgery* 2020;87:744–53.
- Baek JW, Jin S-C, Kim JH, Yoo MW, *et al.* Initial multicentre experience using the Neuroform Atlas stent for the treatment of un-ruptured saccular cerebral aneurysms. *Br J Neurosurg* 2020;34:333–8.
- Cay F, Peker A, Arat A. Stent-assisted coiling of cerebral aneurysms with the Neuroform Atlas stent. *Interv Neuroradiol* 2018;24:263–9.
- Goertz L, Dorn F, Siebert E, *et al.* Safety and efficacy of the Neuroform Atlas for stent-assisted coiling of intracranial aneurysms: a multicenter experience. *J Clin Neurosci* 2019;68:86–91.
- Gross BA, Ares WJ, Ducruet AF, *et al.* A clinical comparison of atlas and LVIS jr stent-assisted aneurysm coiling. *J Neurointerv Surg* 2019;11:171–4.
- Kim CH, Kim YH, Sung SK, *et al.* Clinical safety and effectiveness of stent-assisted coil embolization with Neuroform Atlas stent in intracranial aneurysm. *J Korean Neurosurg Soc* 2020;63:80–8.
- Quintana EM, Valdes PV, Deza EM, *et al.* Initial experience and one-year follow-up with Neuroform Atlas stent system for the treatment of brain aneurysms. *Interv Neuroradiol* 2019;25:521–9.
- Raymond J, Guilbert F, Weill A, *et al.* Long-term angiographic recurrences after selective endovascular treatment of aneurysms with detachable coils. *Stroke* 2003;34:1398–403.
- Ten Brinck MFM, de Vries J, Bartels RHMA, *et al.* Neuroform Atlas stent-assisted coiling: preliminary results. *Neurosurgery* 2019;84:179–89.
- Tsai JP, Hardman J, Moore NZ, *et al.* Early post-humanitarian device exemption experience with the Neuroform Atlas stent. *J Neurointerv Surg* 2019;11:1141–4.
- Ulfert C, Pham M, Sonnberger M, *et al.* The Neuroform Atlas stent to assist coil embolization of intracranial aneurysms: a multicentre experience. *J Neurointerv Surg* 2018;10:1192–6.
- Aydin K, Arat A, Sencer S, *et al.* Stent-assisted coiling of wide-neck intracranial aneurysms using low-profile Leo baby stents: initial and midterm results. *AJNR Am J Neuroradiol* 2015;36:1934–41.
- Grossberg JA, Hanel RA, Dabus G, *et al.* Treatment of wide-necked aneurysms with the low-profile visualized intraluminal support (LVIS jr) device: a multicenter experience. *J Neurointerv Surg* 2017;9:1098–102.

- 16 Zhao B, Yin R, Lanzino G, *et al.* Endovascular coiling of wide-neck and wide-neck bifurcation aneurysms: a systematic review and meta-analysis. *AJNR Am J Neuroradiol* 2016;37:1700–5.
- 17 Ciccio G, Robert T, Smajda S, *et al.* Double stent assisted coiling of intracranial bifurcation aneurysms in Y and X configurations with the Neuroform Atlas stent: immediate and mid term angiographic and clinical follow-up. *J Neurointerv Surg* 2019;11:1239–42.
- 18 Jankowitz BT, Hanel R, Jadhav AP, *et al.* Neuroform Atlas stent system for the treatment of intracranial aneurysm: primary results of the Atlas humanitarian device exemption cohort. *J Neurointerv Surg* 2019;11:801–6.
- 19 Granja MF, Cortez GM, Aguilar-Salinas P, *et al.* Stent-assisted coiling of cerebral aneurysms using the Y-stenting technique: a systematic review and meta-analysis. *J Neurointerv Surg* 2019;11:683–9.
- 20 Park S-Y, Oh J-S, Oh H-J, *et al.* Safety and efficacy of low-profile, self-expandable stents for treatment of intracranial aneurysms: initial and midterm results - a systematic review and meta-analysis. *Interv Neurol* 2017;6:170–82.
- 21 Cagnazzo F, Cappucci M, Lefevre P-H, *et al.* Treatment of intracranial aneurysms with self-expandable braided stents: a systematic review and meta-analysis. *AJNR Am J Neuroradiol* 2018;39:2064–9.
- 22 Zaidat OO, Hanel RA, Sauvageau EA, *et al.* Pivotal trial of the Neuroform Atlas stent for treatment of anterior circulation aneurysms: one-year outcomes. *Stroke* 2020;51:2087–94.
- 23 Caragliano AA, Papa R, Pitrone A, Limbucci N, *et al.* The low-profile Neuroform Atlas stent in the treatment of wide-necked intracranial aneurysms - immediate and midterm results: an Italian multicenter registry. *J Neuroradiol* 2020;47:421–427.
- 24 Hanel RA, Yoon N, Sauvageau E, *et al.* Neuroform Atlas stent for treatment of middle cerebral artery aneurysms: 1-year outcomes from Neuroform Atlas stent pivotal trial. *Neurosurgery* 2021;89:102–8.
- 25 Zhang S-M, Liu L-X, Ren P-W, *et al.* Effectiveness, safety and risk factors of Woven EndoBridge device in the treatment of wide-neck intracranial aneurysms: systematic review and meta-analysis. *World Neurosurg* 2020;136:e1–23.
- 26 Cagnazzo F, Mantilla D, Lefevre P-H, *et al.* Treatment of middle cerebral artery aneurysms with flow-diverter stents: a systematic review and meta-analysis. *AJNR Am J Neuroradiol* 2017;38:2289–94.

Supplement

Figure 1 : Patient Disposition Flow Chart



- [1] One patient died before discharge.
[2] One patient missed the 3 month follow up but completed the 12 to 16 month follow up.
[3] One patient died before the 12 to 16 month follow up.

Table 1: Site-Reported Technical Results (mITT)

Measure	Results
Total Duration of Procedure (mins)	
Mean ± SD (N)	109.8±55.8 (105)
Median (Q1-Q3)	95 (70-136)
Range (Min-Max)	340 (35-375)

Measure	Results
Type of Anesthesia	
General Anesthesia	100.0% (105/105)
Number of Neuroform Atlas Stents Attempted	
1	78.1% (82/105)
2	20.0% (21/105)
3	1.0% (1/105)
4	1.0% (1/105)
Number of Neuroform Atlas Stents Implanted	
1	81.0% (85/105)
2	17.1% (18/105)
3	1.9% (2/105)
If more than one stent implanted, specify the configuration technique	
Y-Stent	90.5% (19/21)
Telescopic	4.8% (1/21)
Other ¹	4.8% (1/21)
Packing Density	
Mean \pm SD (N)	47.1 \pm 31.1 (11)
Median (Q1-Q3)	30 (25-90)
Range (Min-Max)	80 (20-100)
Coil Delivery Technique used	
Crossing technique	32.4% (34/105)
Jailing	61.0% (64/105)
Other	6.7% (7/105)
Procedural Complications/Adverse Event during the Procedure	6.7% (7/105)
Administration of antithrombotic and/or antiplatelet and/or anticoagulant medications during procedure	100.0% (105/105)
Single or Dual Anti-platelet Therapy	
None	2.9% (3/105)
Single	23.8% (25/105)
Dual	73.3% (77/105)
Number of Microcatheters used	
0	1.0% (1/105)
1	32.4% (34/105)
2	61.0% (64/105)
3	4.8% (5/105)
4	1.0% (1/105)

Measure	Results
Other adjunctive devices	12.4% (13/105)
Balloon	69.2% (9/13)
Other	30.8% (4/13)
¹ One patient received 2 different stent devices using telescopic technique.	